Evening Symposium, Toolbox for Complex PCI

November 29 6:20 PM ~ 6:30 PM

Debulking Devices: Unload Your Tough, Calcified Burden

Cardiovascular Center, Sakurabashi Watanabe Hospital

Atsunori Okamura

1. Scorering balloons

2. Crushing with PCI stiff wires

3. Rotablation

Rotablator

	Burr size	Spin speed
Necessary use of Rota		
• Sever calcified lesion which can not be open by POBA. **Case1, 2**	burr size: B/A: 0.6 or 1.25mm or 1.5mm	200,000 rpm-Max.
Additional use of Rota		
Lesion modification • Improvement of the deliverbility of DES and prevention of polymer damage during the delivery of stent through the calcified plaque. • Enough expansion of the stent struts for adequate effect	B/A: 0.6-0.8 or Expected ablated depth from IVUS is 0.25mm, therefore 1.5-1.75mm burrs are usually used.	200,000 rpm-Max.
Aggressive Rota • Aggressive ablation for the sever calcified lesion due to Hemodialysis.	B/A: 0.7-0.8 or 2mm burr might be effective for prevention of restenosis, but ≤1.75mm burr is usually used to avoid the slow flow.	200,000 rpm-Max.
• Ablation of the bifurcation to avoid the double stenting (Distal LMCA, LAD & Dx bifurcations). **Case3**	B/A: 0.6 Burr size depends on the side branch angulation. 1.5-1.75mm burr for LCX and 1.5mm for the other bifurcations.	180,000 rpm

Case1. Sever calcified lesions in the mid-LAD which could not be dilated with POBA, and in the distal LAD which could not be passed even with Rota 1.25-mm burr.

Mid- LAD lesion could be ablated with 1.5mm burr, but distal LAD lesion could not be ablated with 1.25mm burr.

Mid- LAD lesion could be ablated with 1.5mm burr.

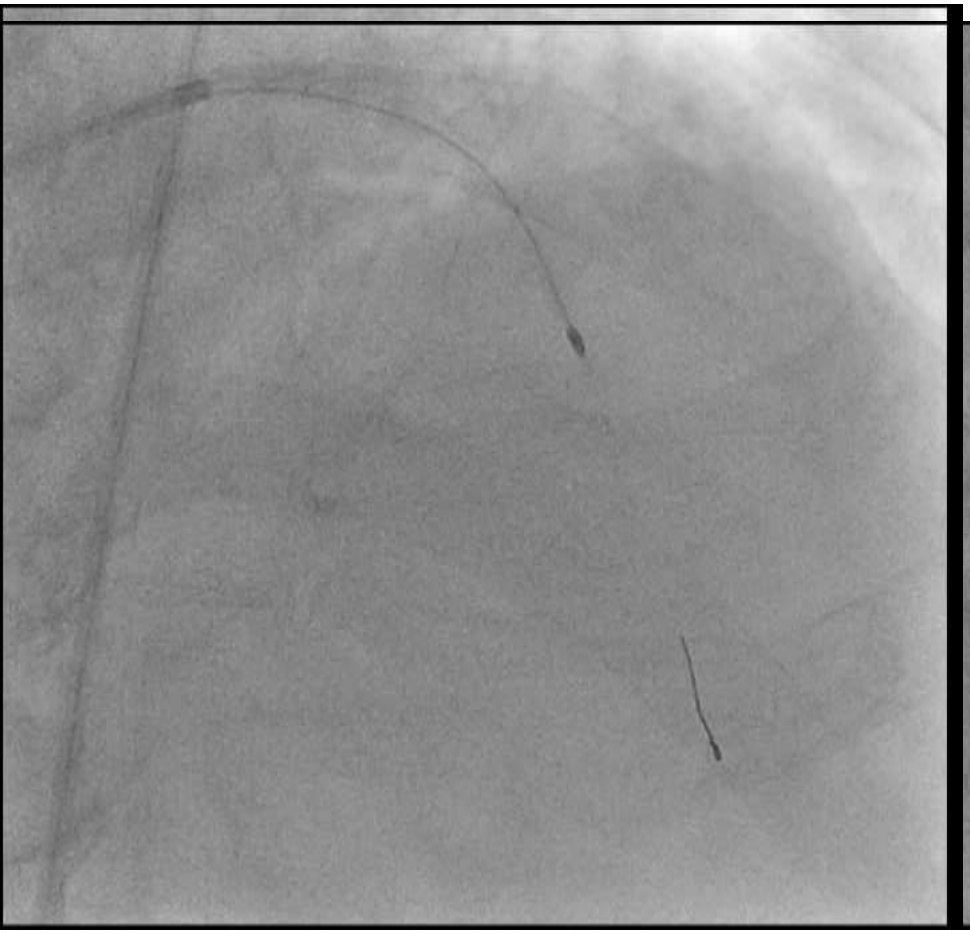

Distal LAD lesion could not be ablated with 1.25mm burr.

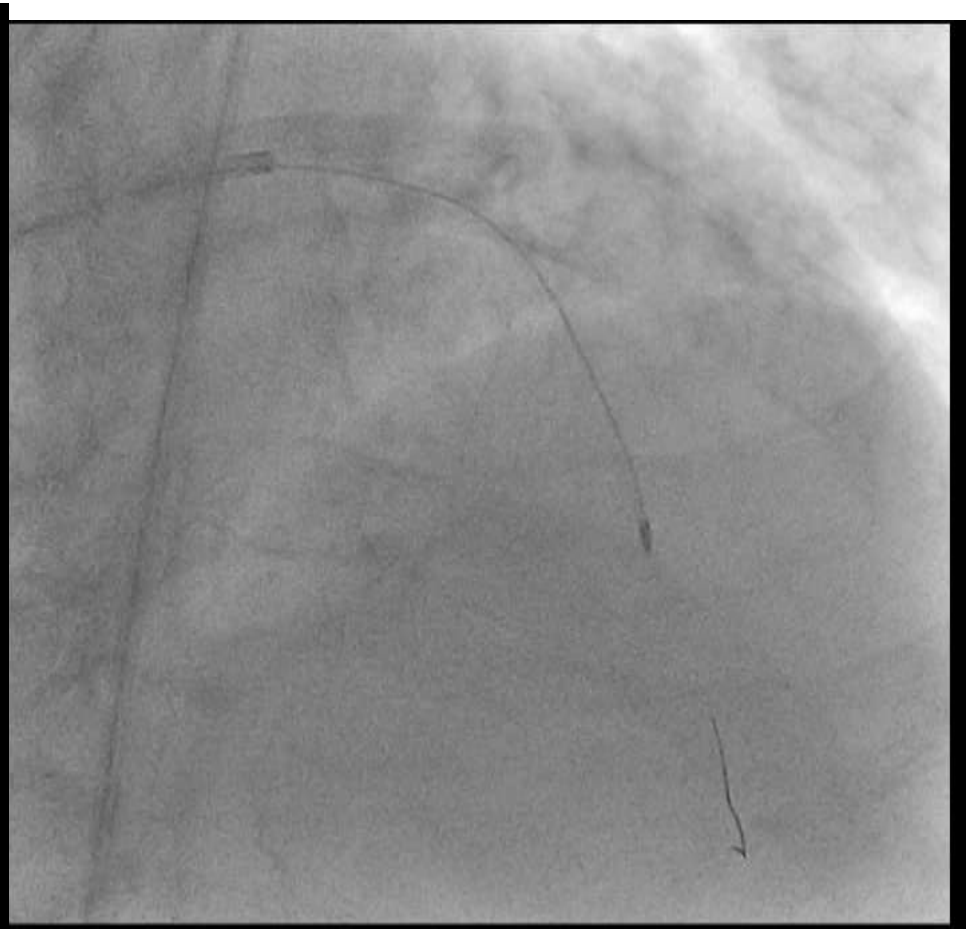

The balloon also could not be passed the distal calcified plaque, which was crushed with PCI stiff wires (Miracle12g, Conquest pro).

A 1.0-mm balloon Sapphire 2 and Tornus could not pass the distal-LAD lesion with sever calcification.

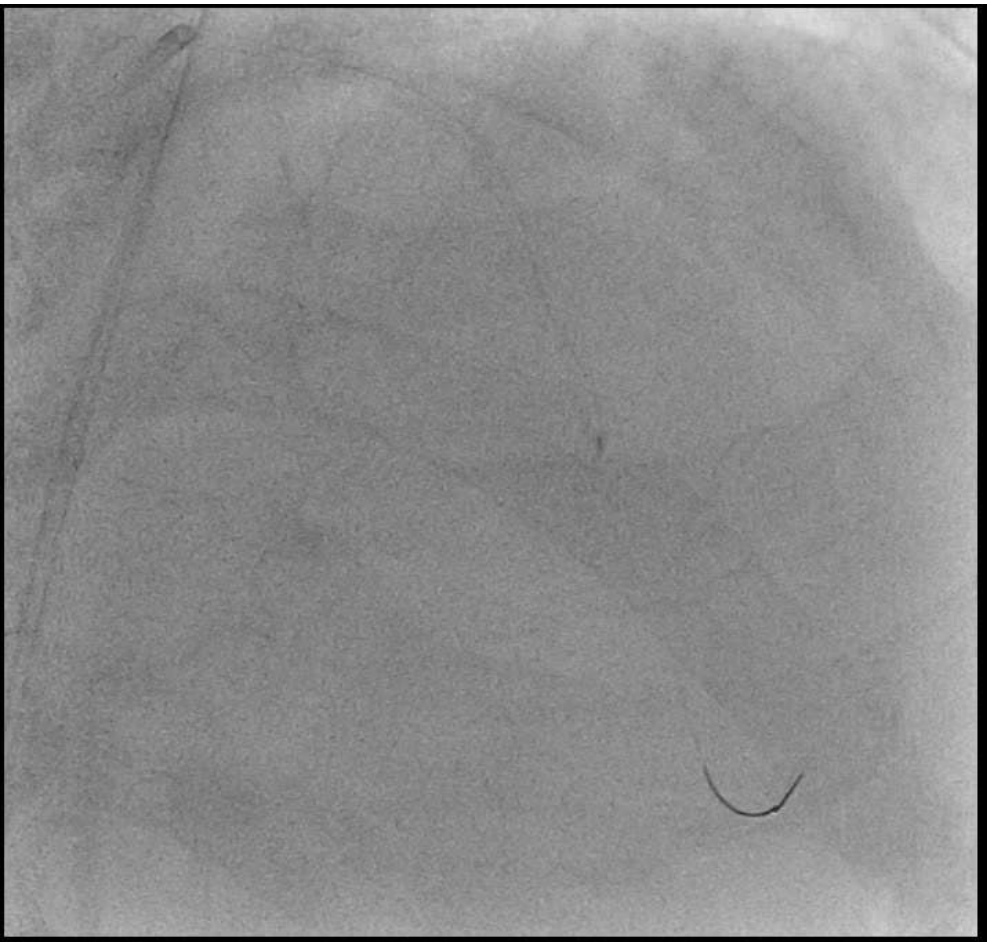

Plaque crushing with PCI stiff wires.

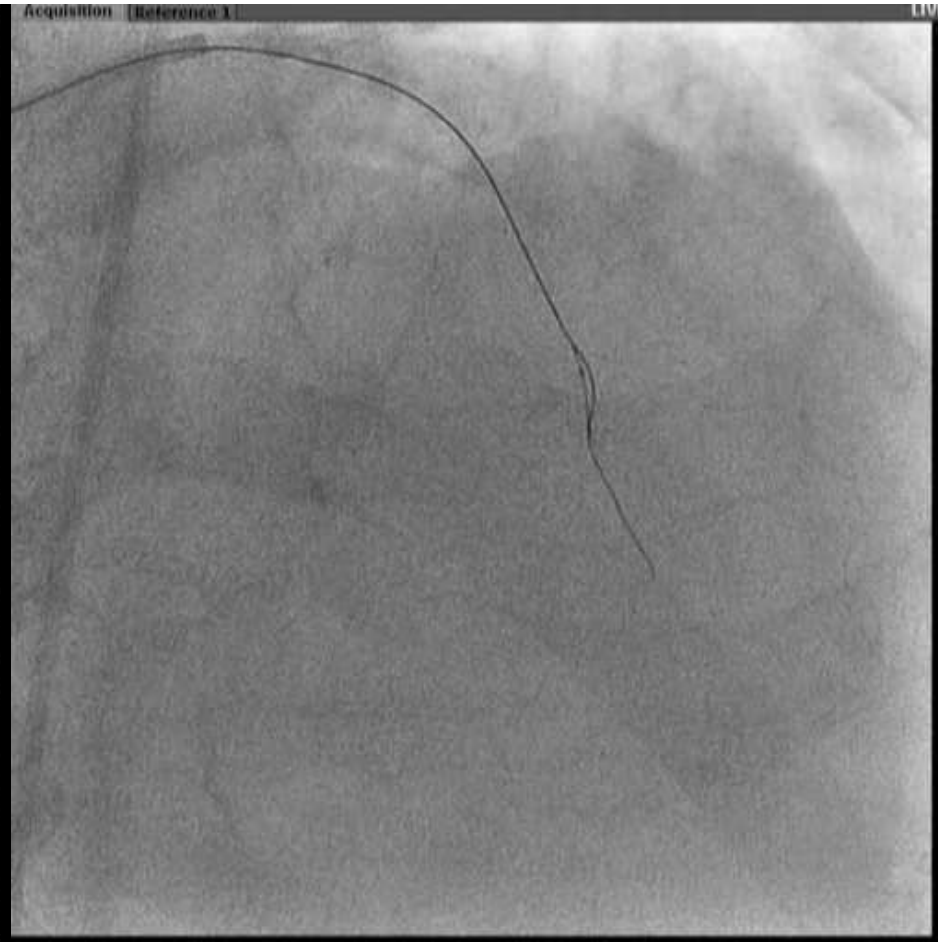

After crushing the plaque with the stiff wires, 1.25mm burr could be easily passed followed by POBA.

Rota 1.25mm burr was passed, followed by successful balloon dilatation.

A 2.5-mm NC balloon could not dilate LAD middle lesion at 22atm.

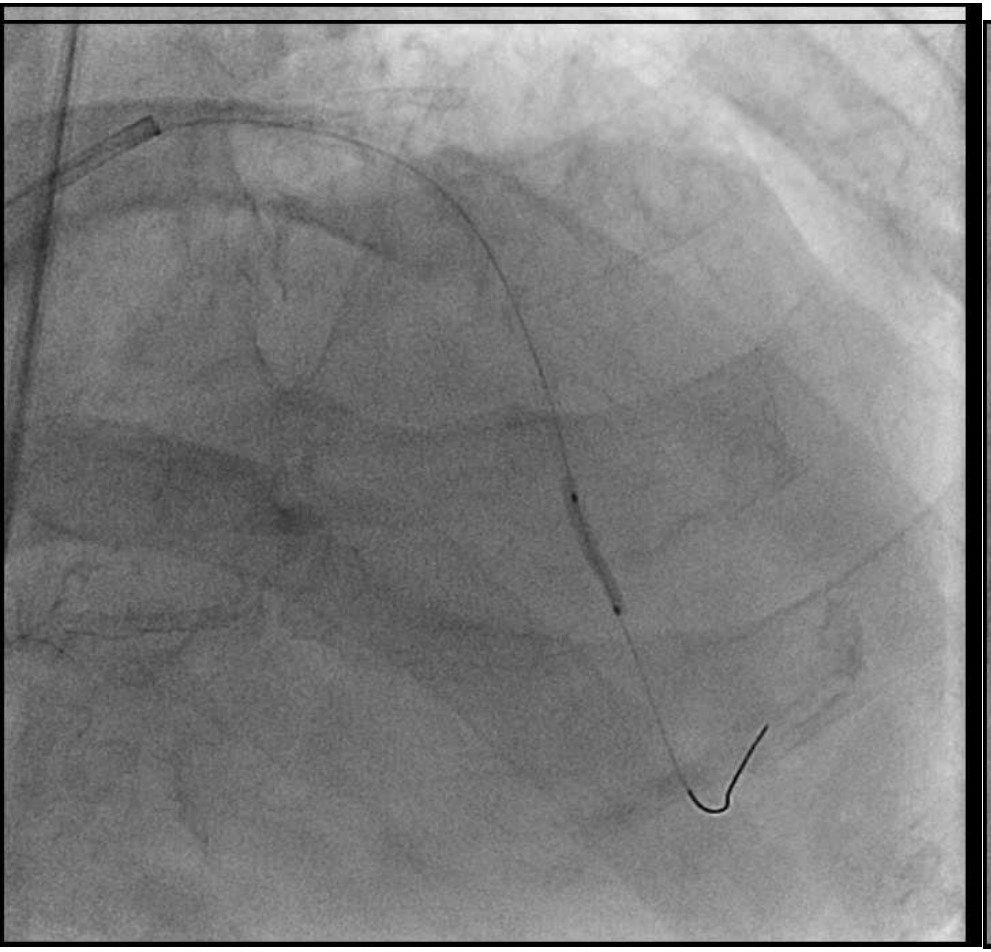

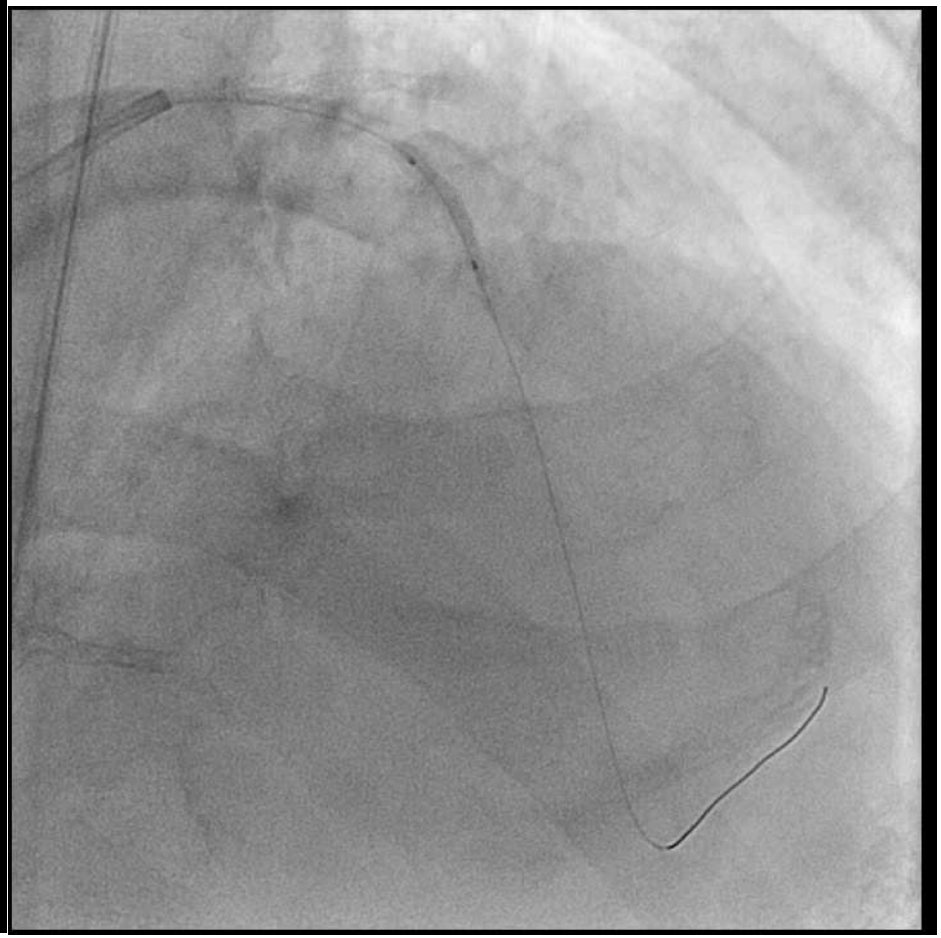

A 2.5-mm Scoreflex balloon could fully dilate the LAD mid lesion at 16atm.

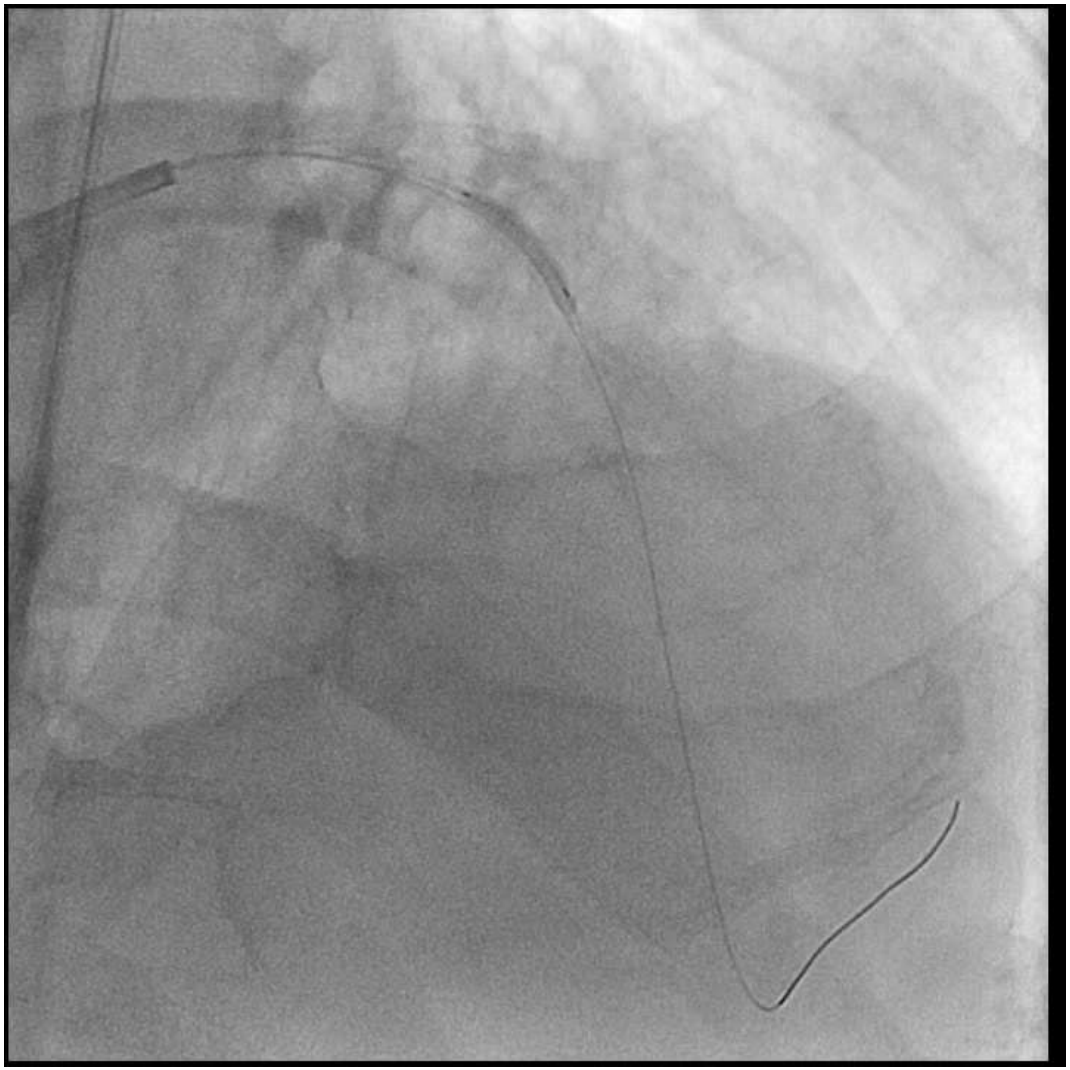

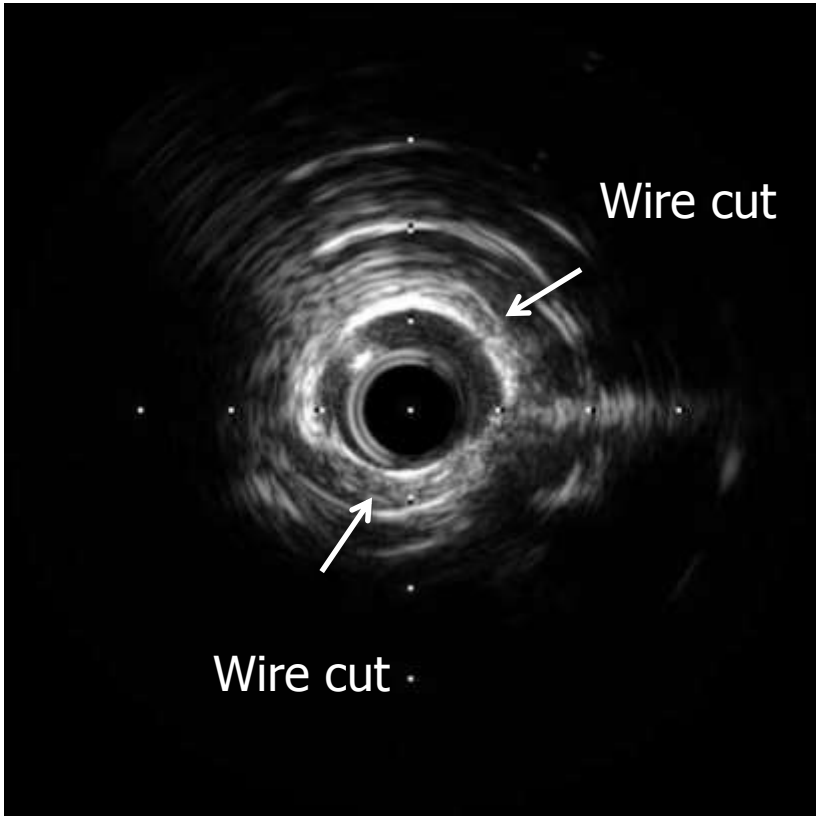

Two drug eluting stents were implanted and TIMI-3 flow was obtained.

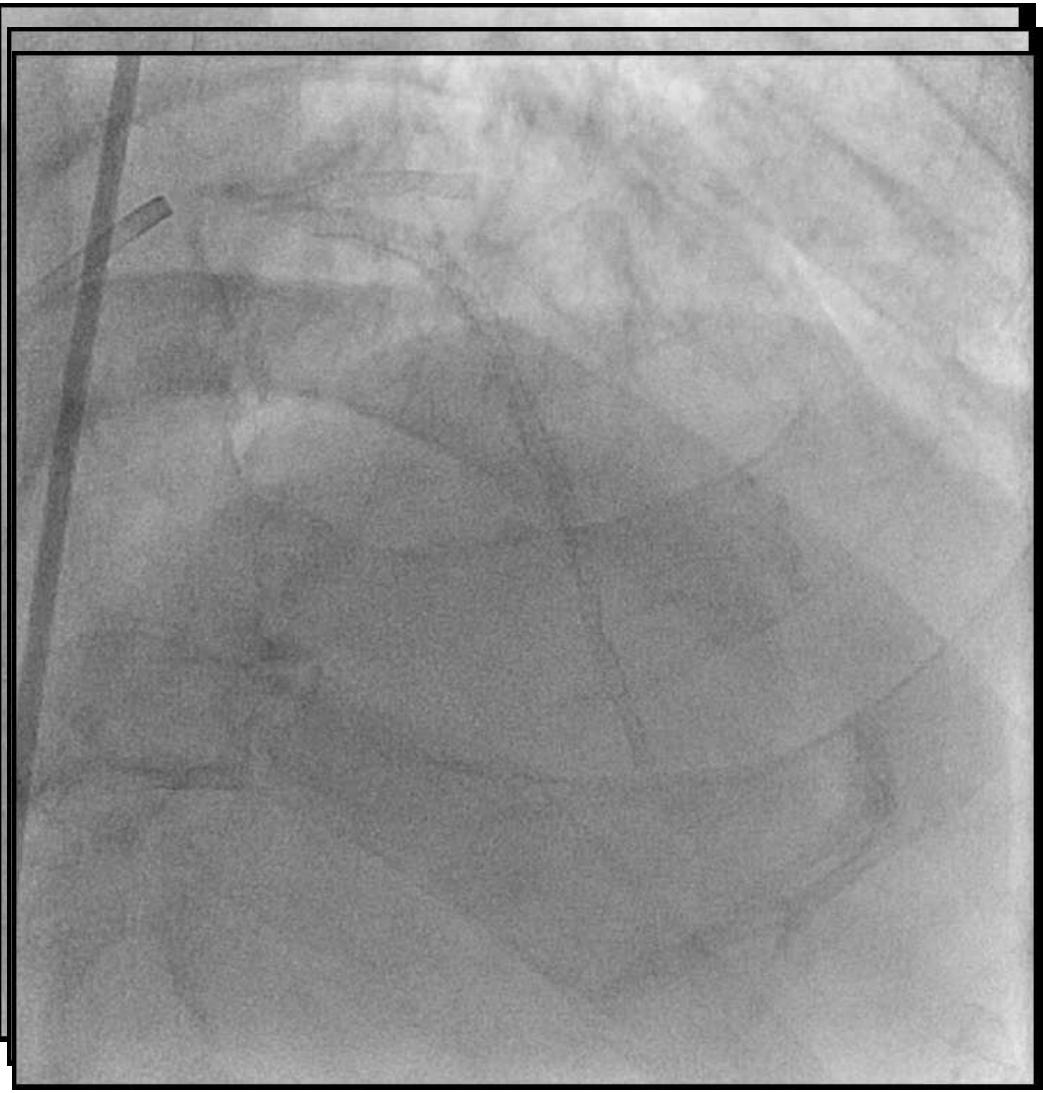

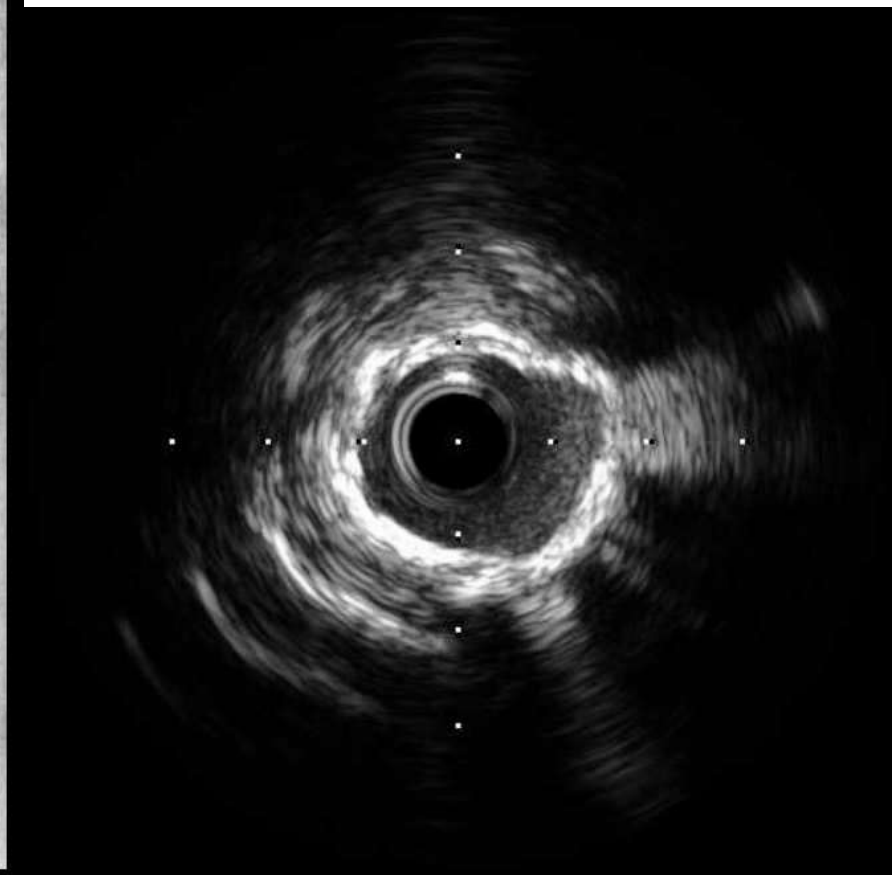

Case2. In-stent restenosis lesion due to stent under-expansion.

The lesion at Seg1 was treated by a 3.5x32mm DES. Because of the under-expansion of the DES, in-stent occlusion was occurred in the chronic phase.

The DES was not fully dilated by a 3.5-mm NC balloon.

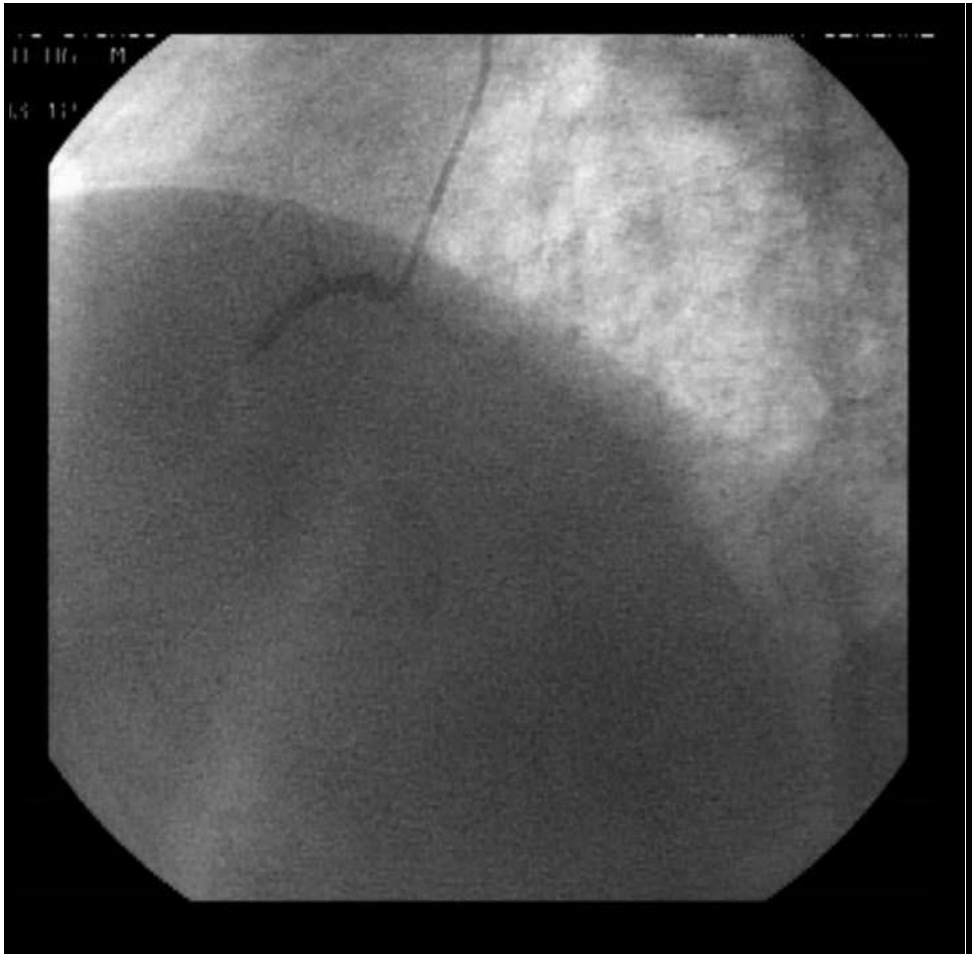

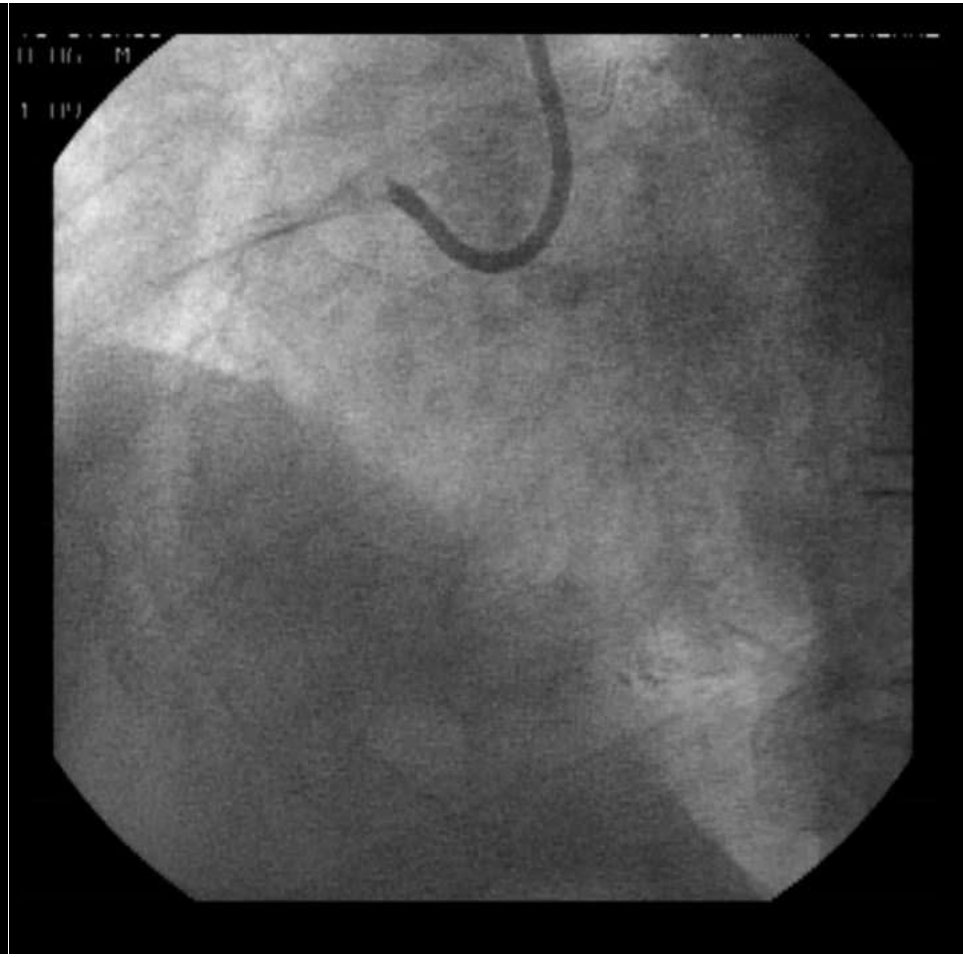

Re-occlusion was occurred in the chronic phase and the GW could not pass through the lesion using parallel wire technique.

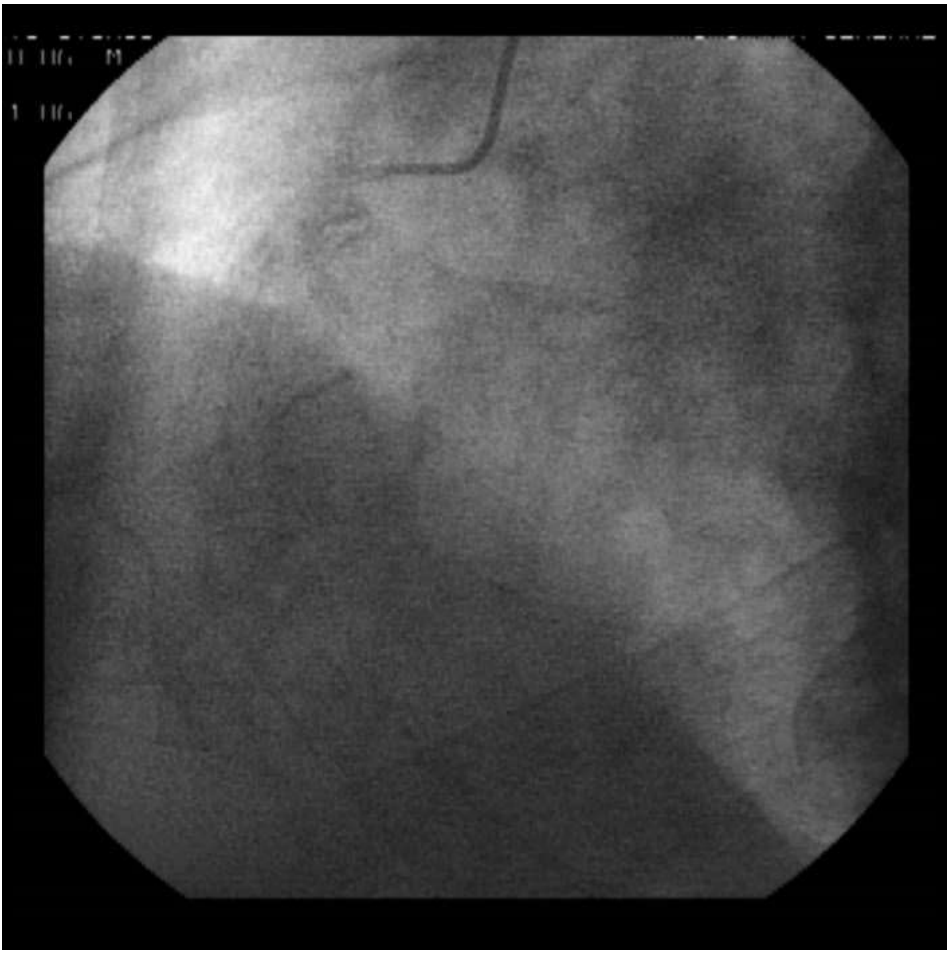

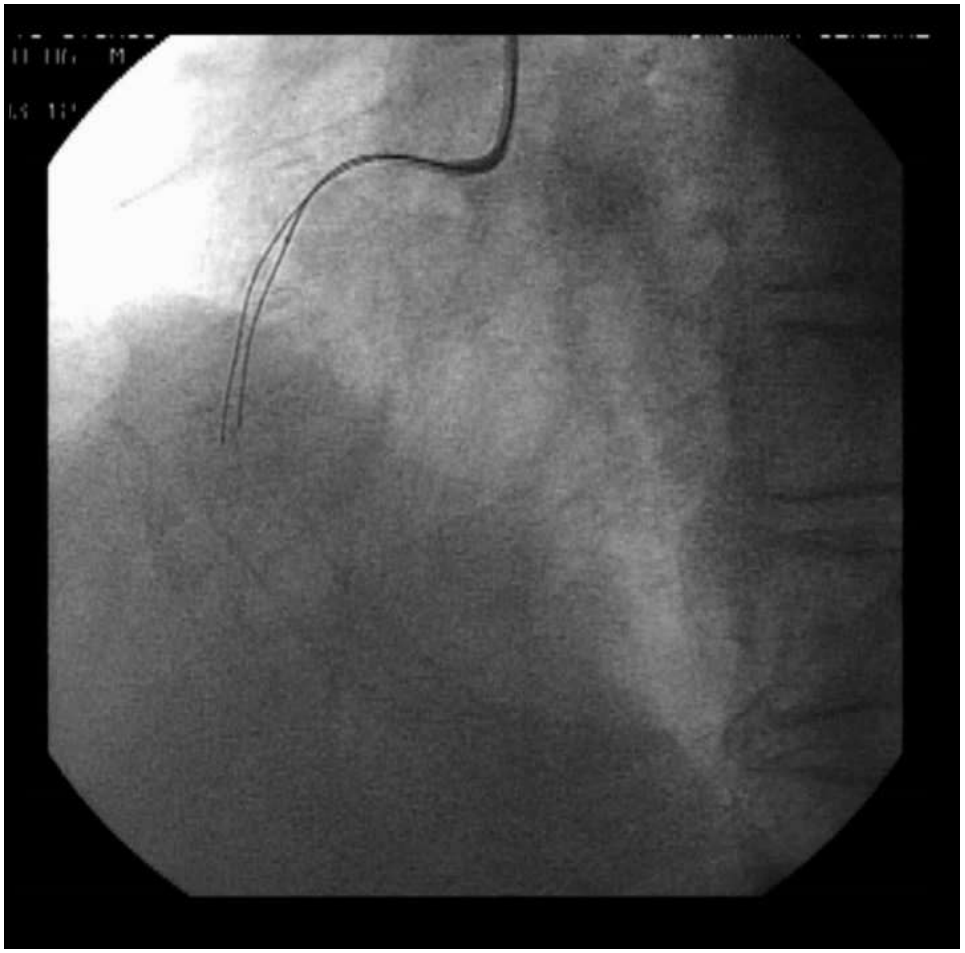

Re-try of Seg1 PCI for ISR CTO PCI lesion
Antegrade: AL SH 8F GC
Antegrade → Retrograde → POBA with 2.5mm balloon

IVUS: stent under-expansion due to the calcified plaque behind the stent

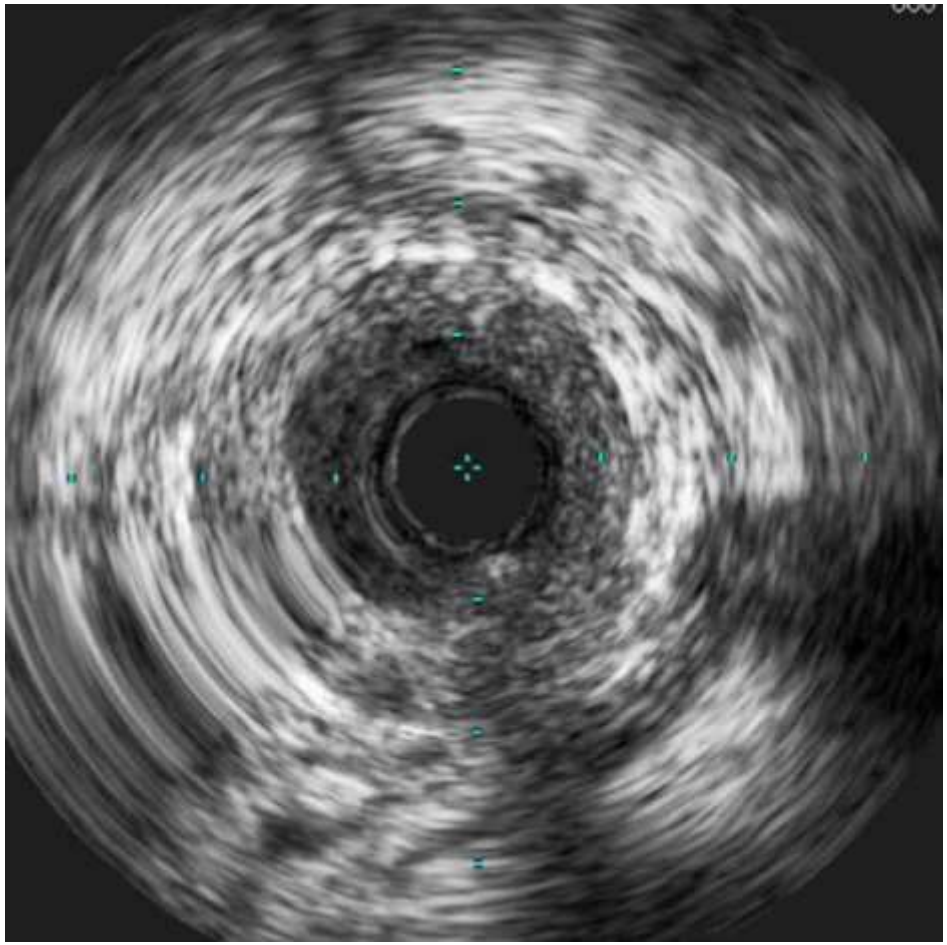

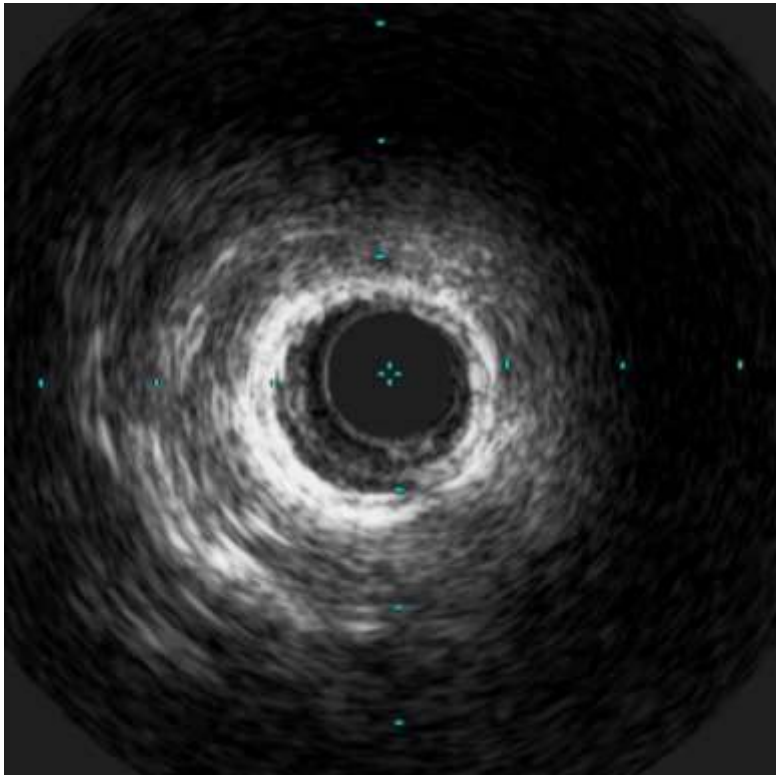

Stent ablation by Rotablator with a 1.75 → 1.5 → 1.75mm burr

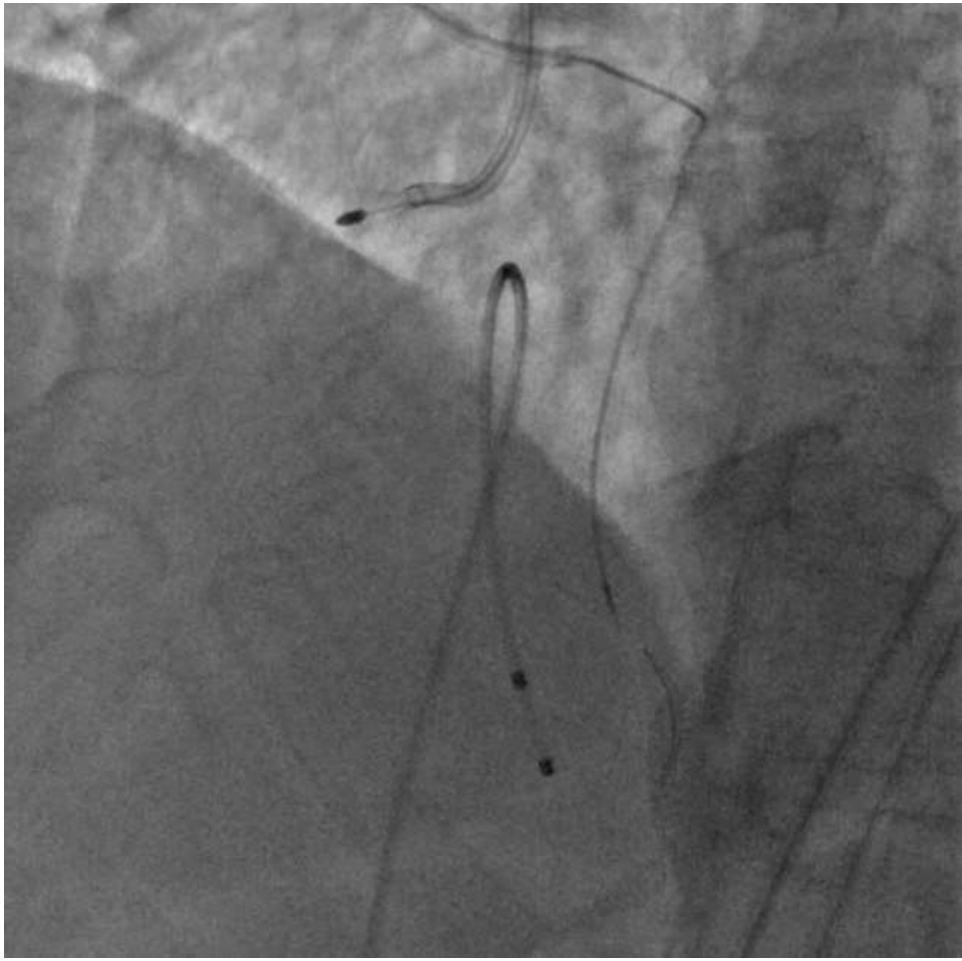

POBA using a 3.5-mm NC balloon after Rotablation with a 1.75mm burr.

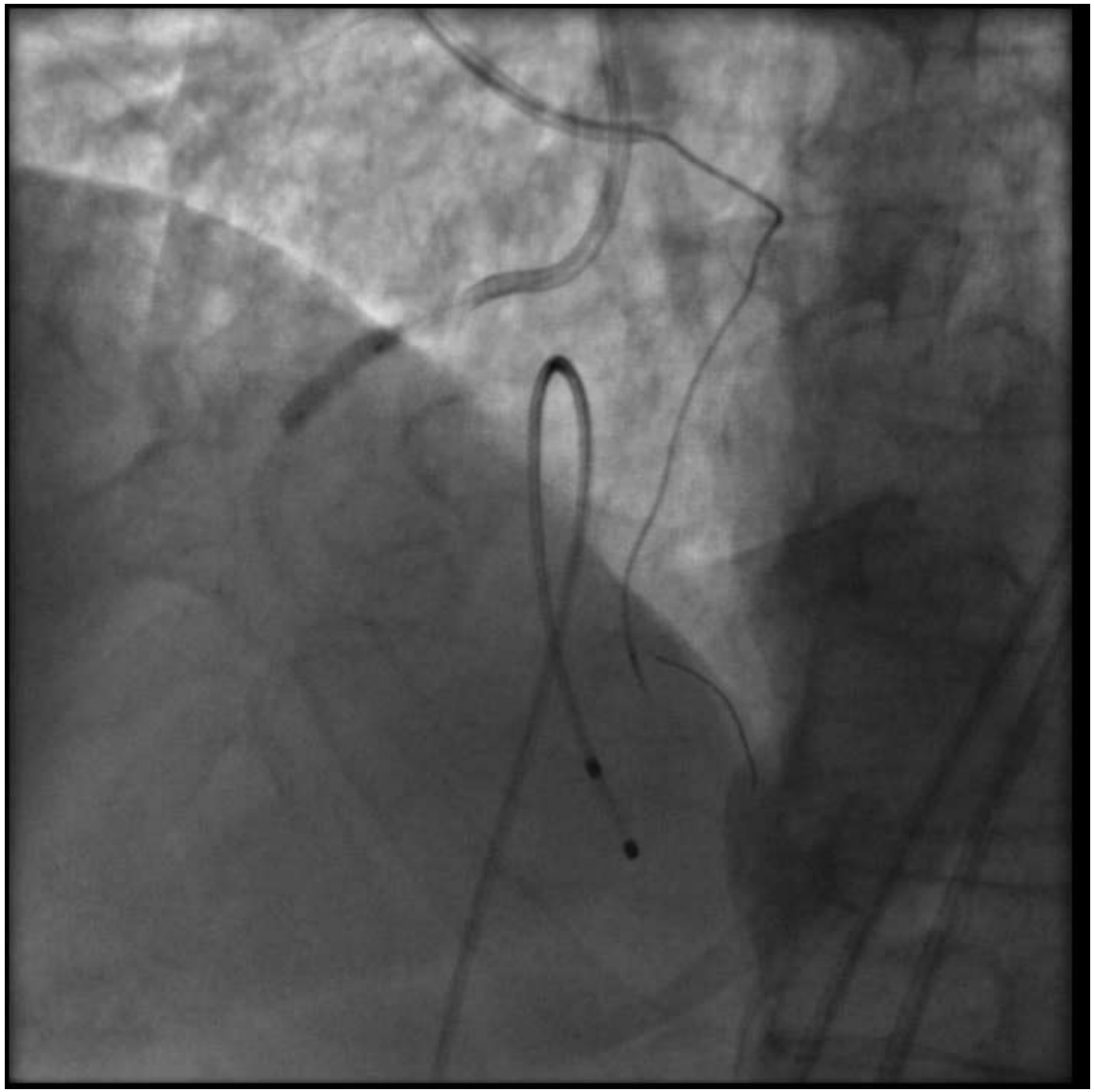

Ablation of the sever calcified plaque behind the stent struts by a Rota 2.25mm burr.

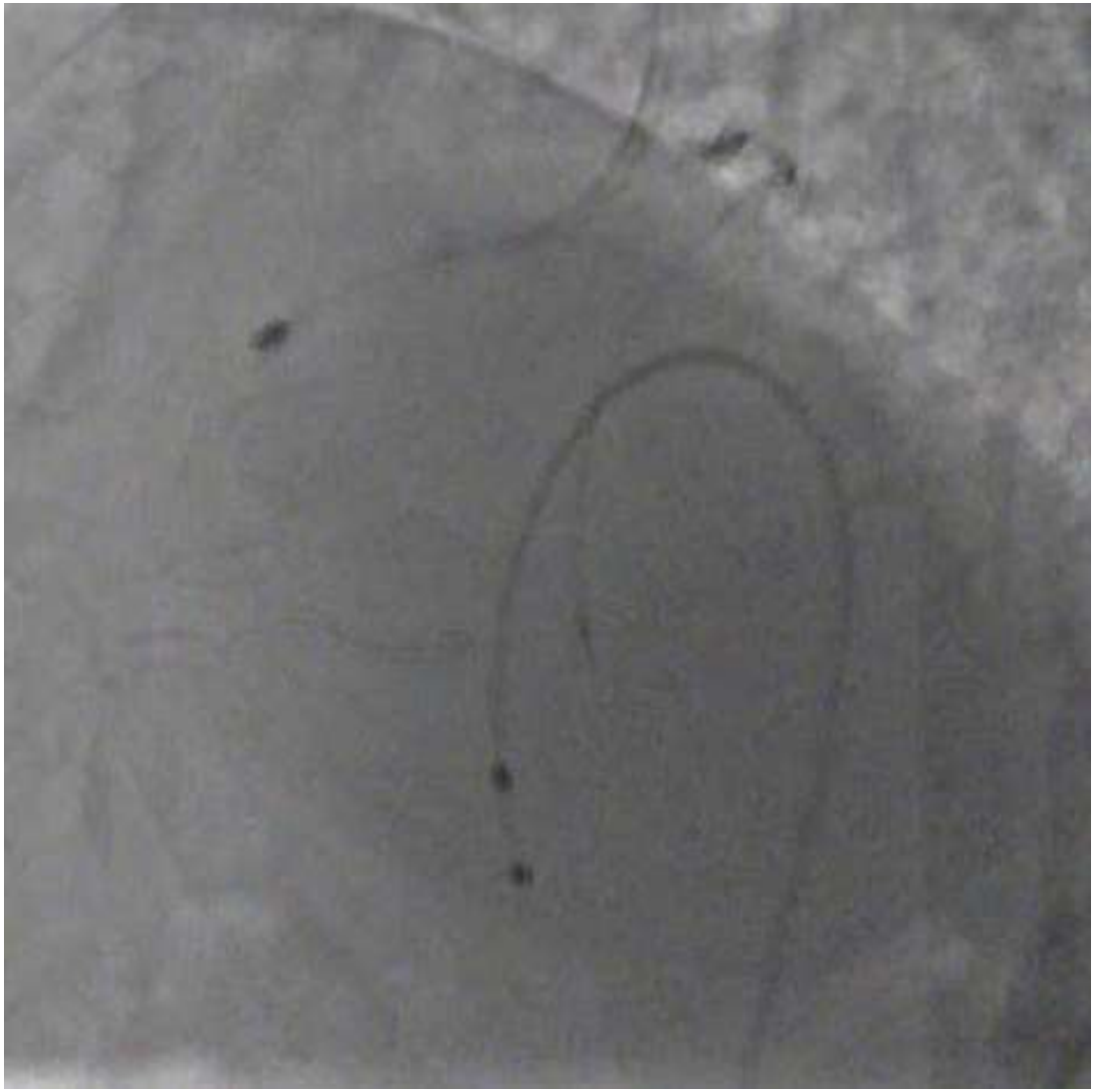

After Rota 2.25mm burr

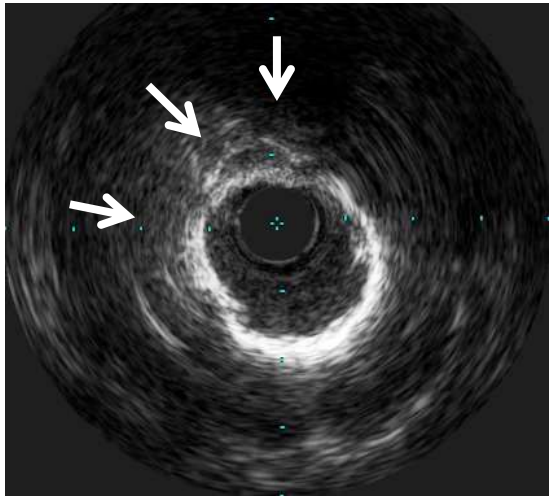

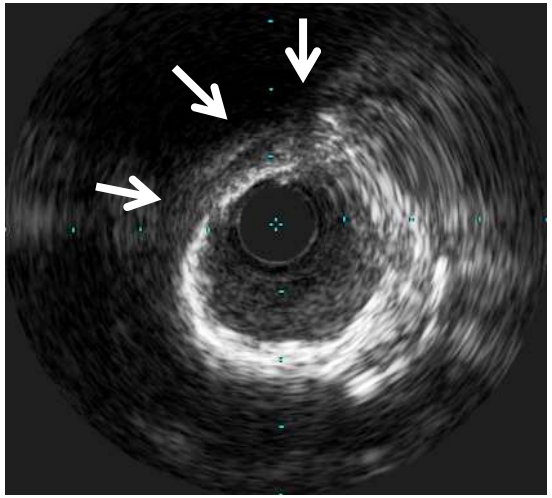

After fully balloon dilatation with a 3.5-mm NC balloon, DES was implanted

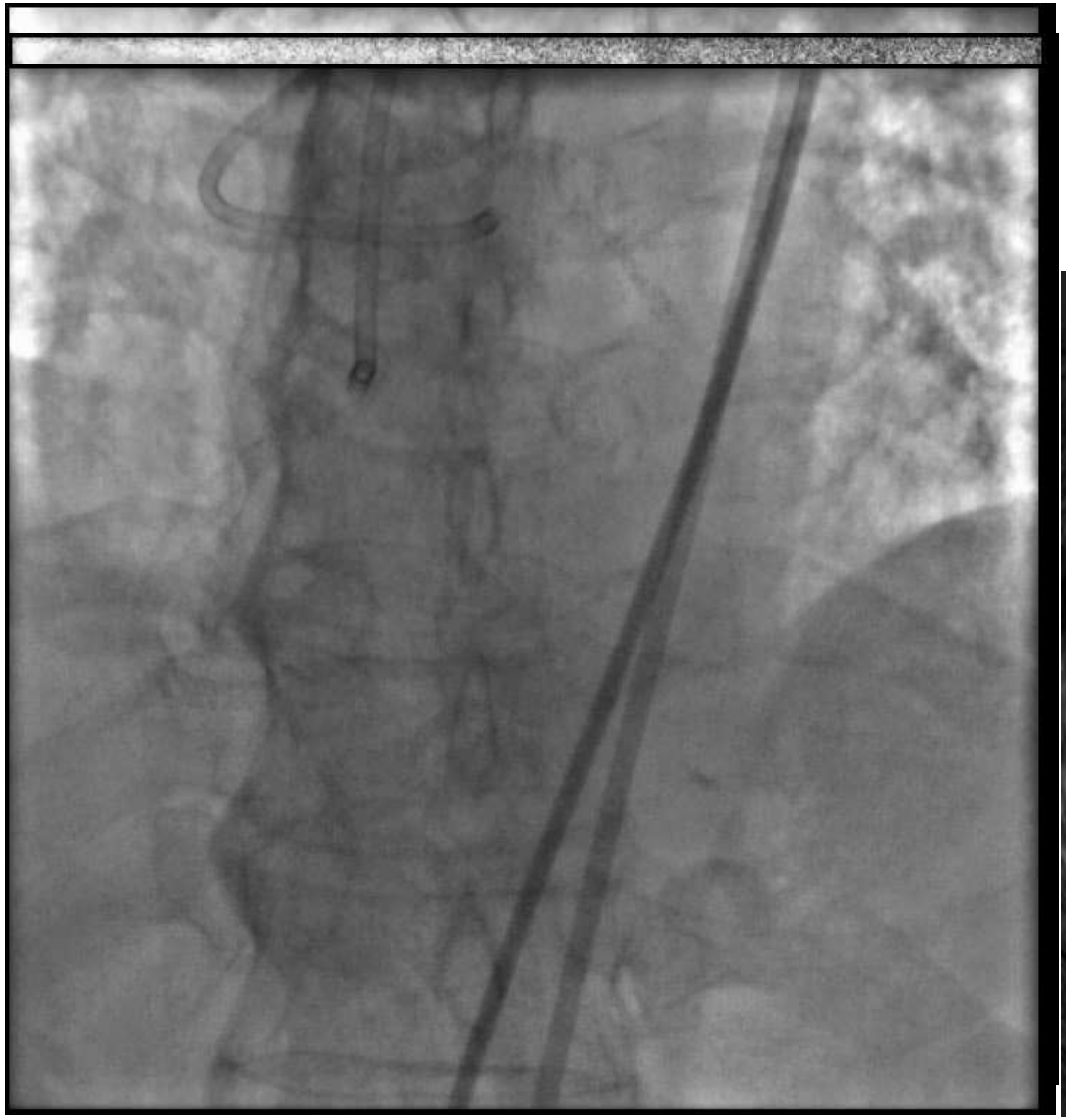

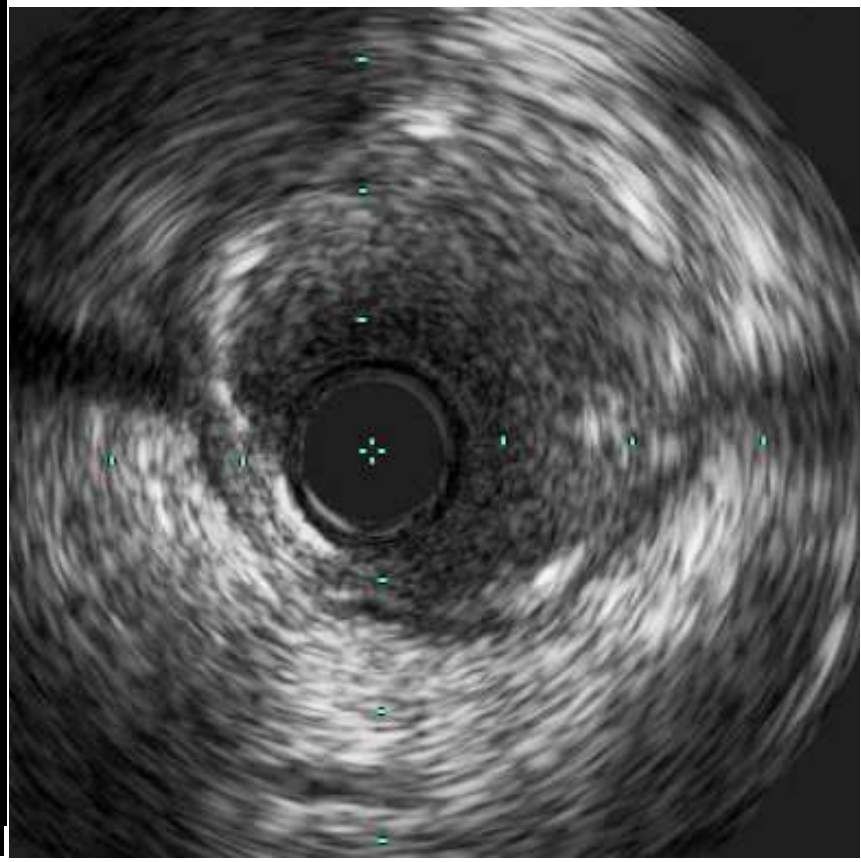

Technique information about the ablation for the stent under-expanded lesion

The optimal Rota burr size should be selected for ablation of stent struts at first and the burr size should be sized up for ablation of calcified plaque after that.

According to the in-vitro experiment, the size of particles generated from the stent struts by stentablation was almost equal size to red blood cell ‘about 5.6 μm

A 3.5×23-mm sirolimus-eluting stent

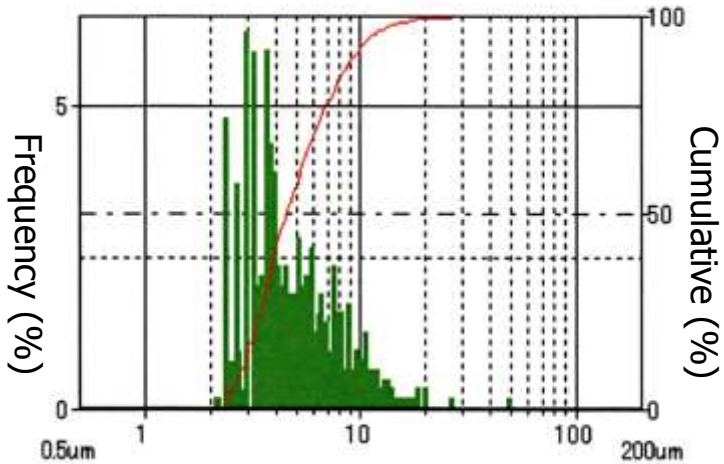

The number of particles was 644.
Size was 5.6±3.6 μm in diameter.

Okamura A, J Invasive Cardiol. 2009; 21:E191-6.

Case3. LMT bifurcation lesion with sever calcification

Target lesions:

LCX Seg11 99%, Seg12 75%

LAD Seg6 90%, Seg5 50%

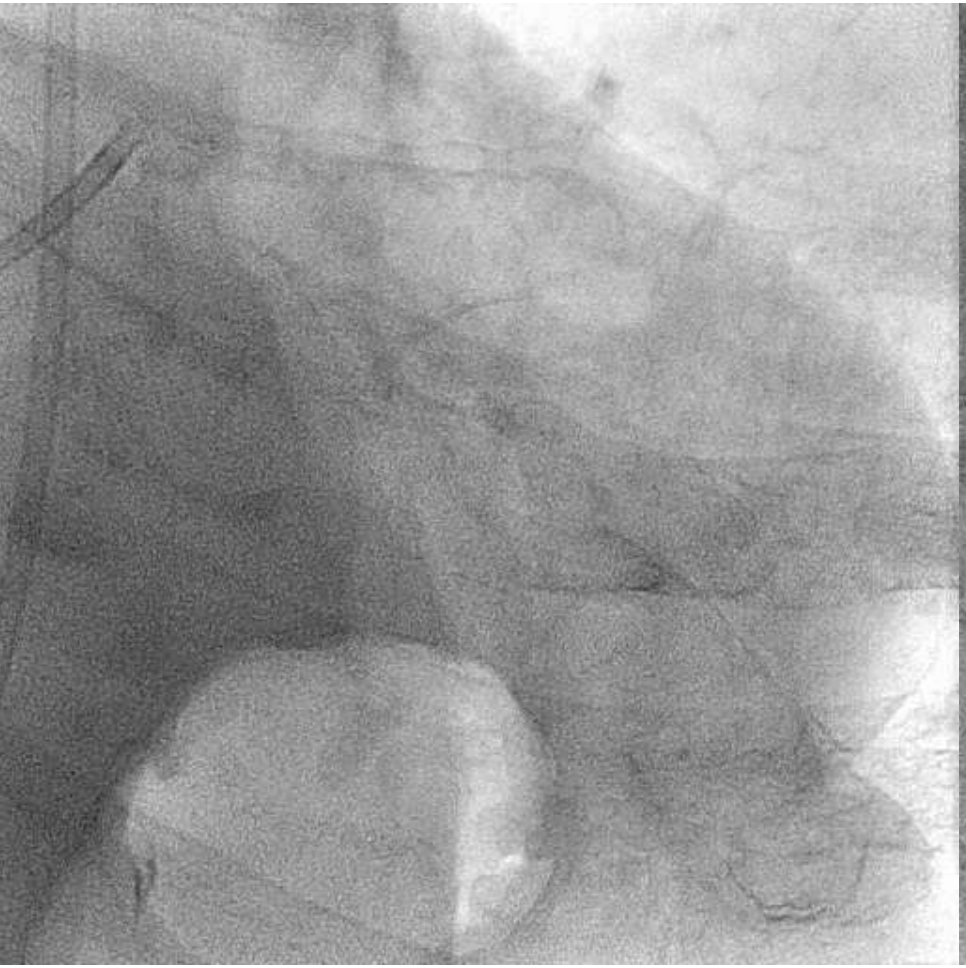

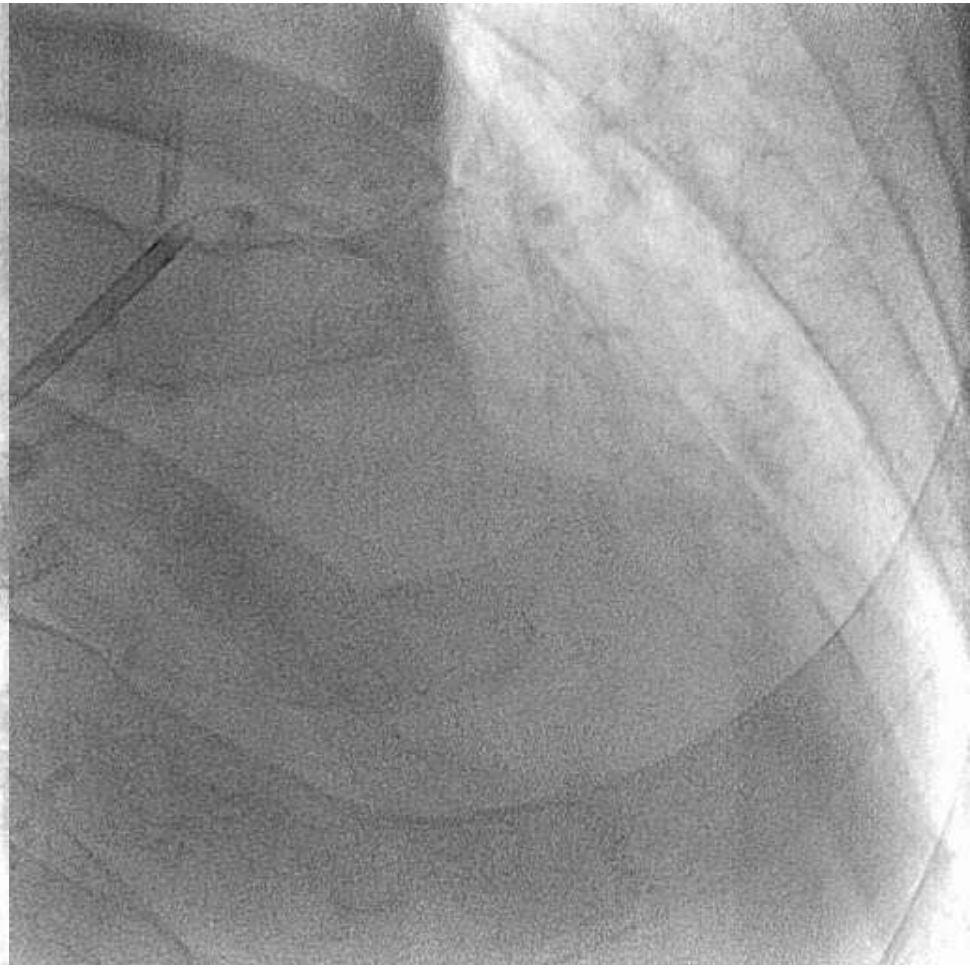

EBU 3.5 guide-catheter was used.
Rota support wire was advanced into the OM branch to ablate the eccentric plaque at Seg11 safely.

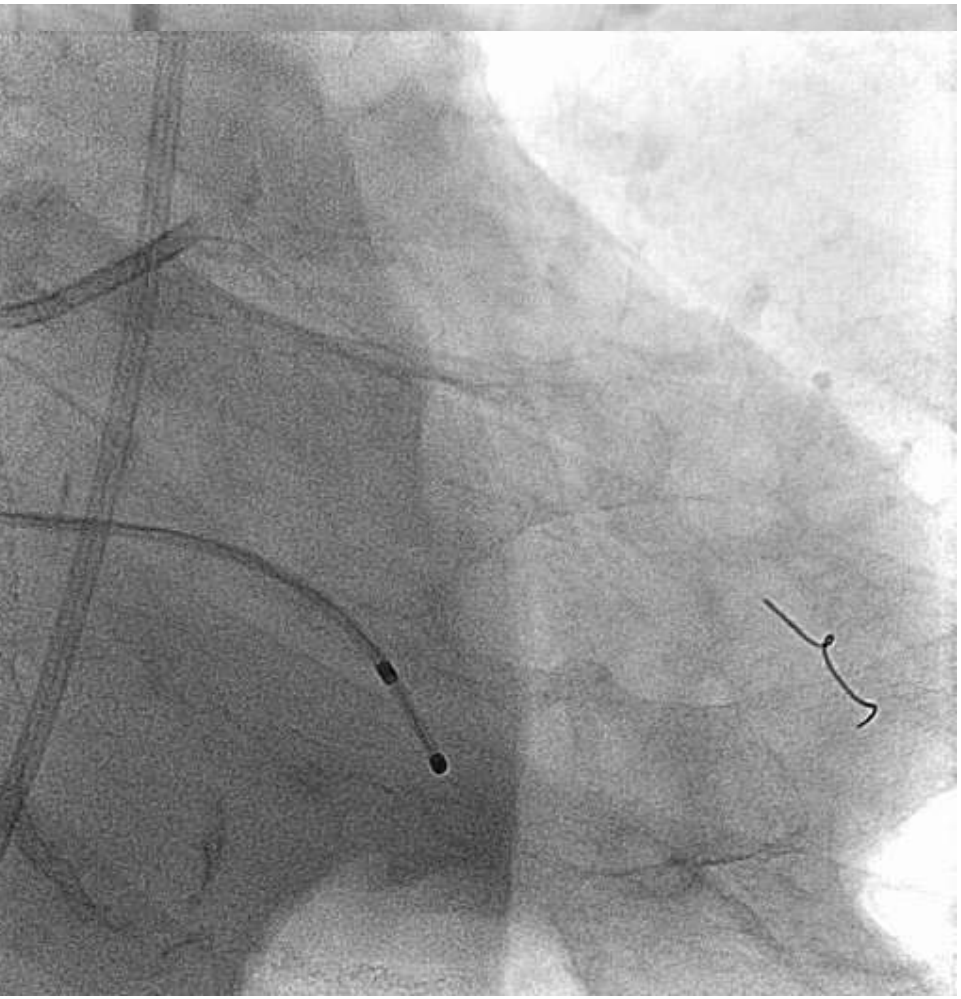

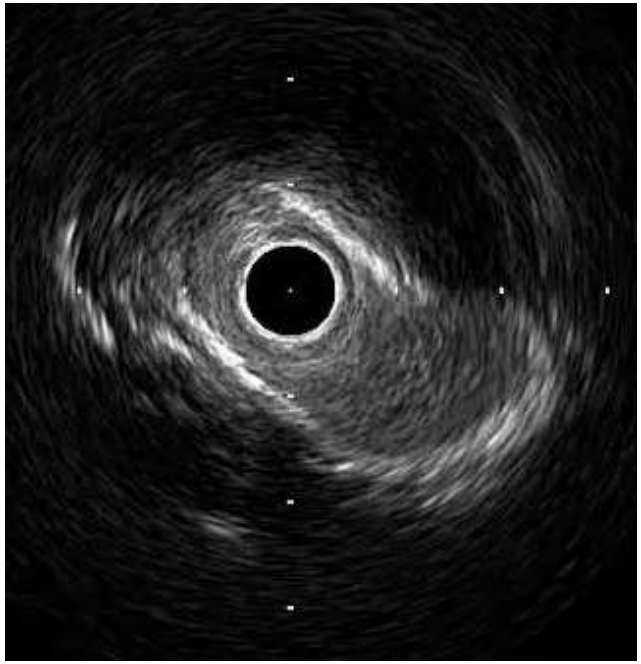

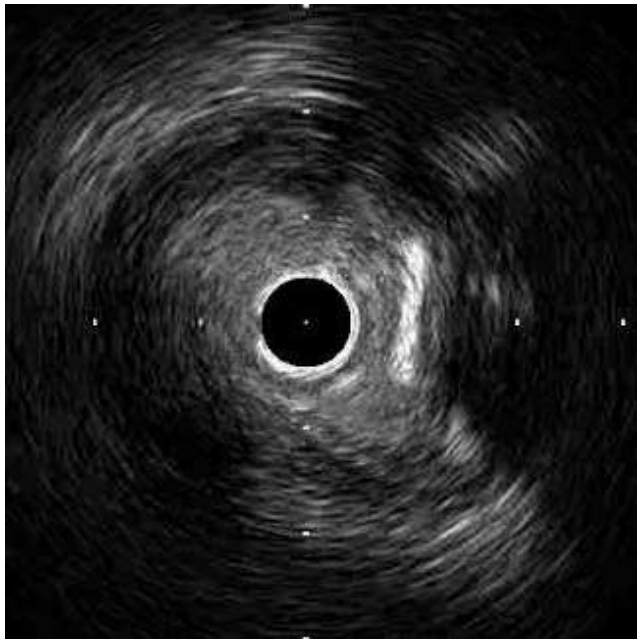

The 1.75mm burr. was used to ablate the proximal LCX.

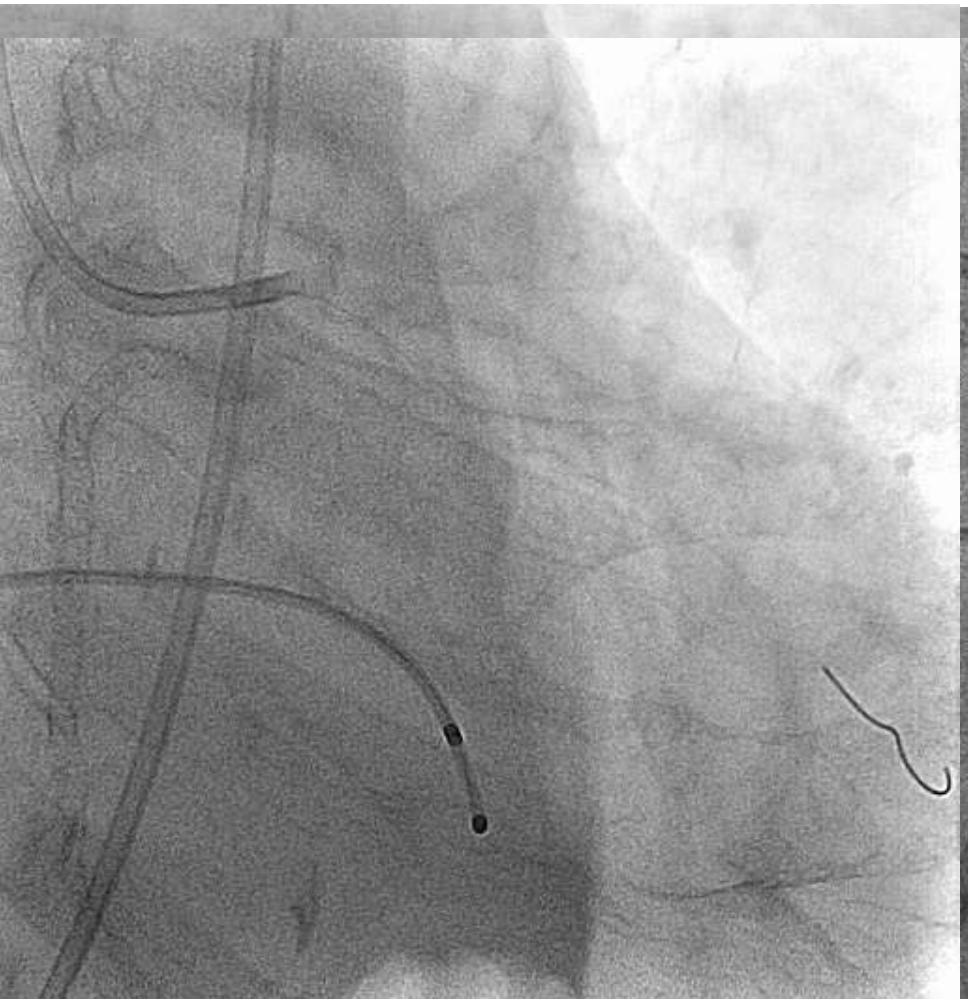

A 1.5mm burr was used to ablate the ostium at Seg12.

To ablate the eccentric plaque at Seg11 aggressively, Rota support wire was advanced to branch of seg14.

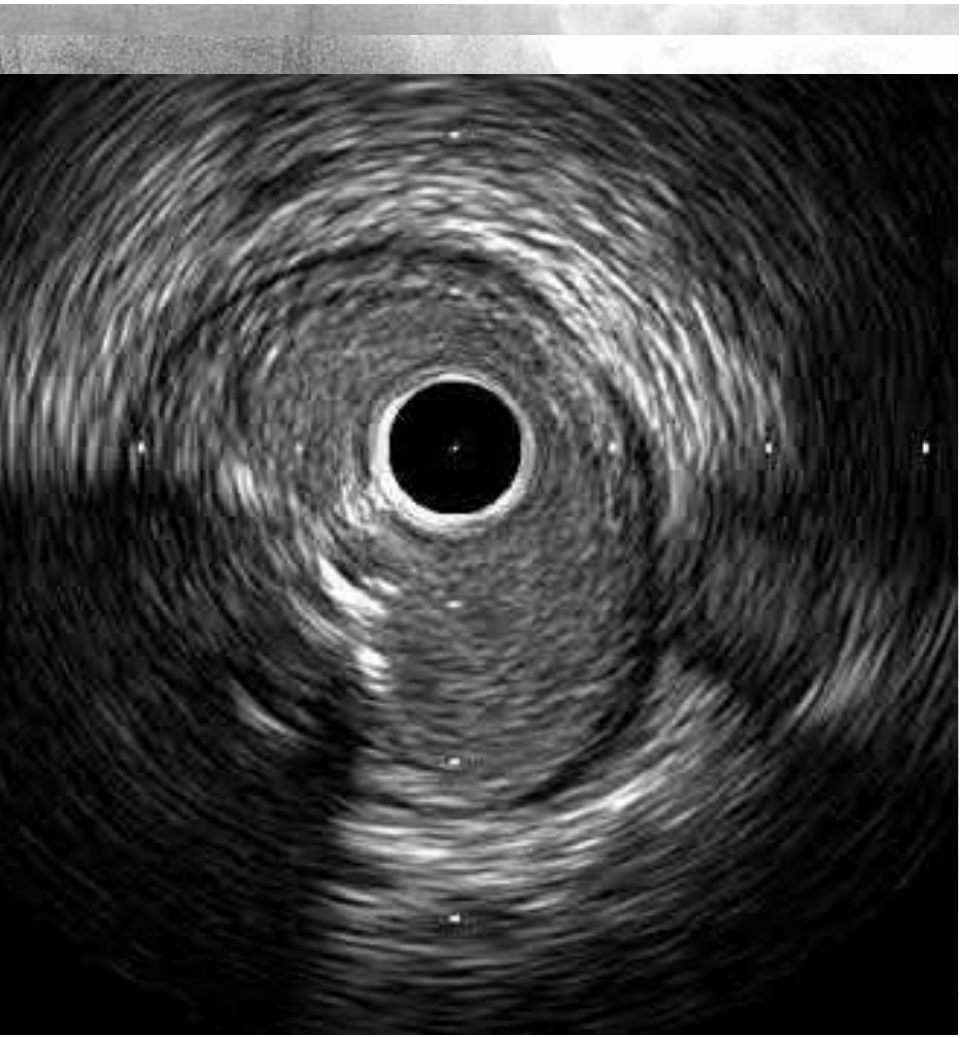

Before Rota

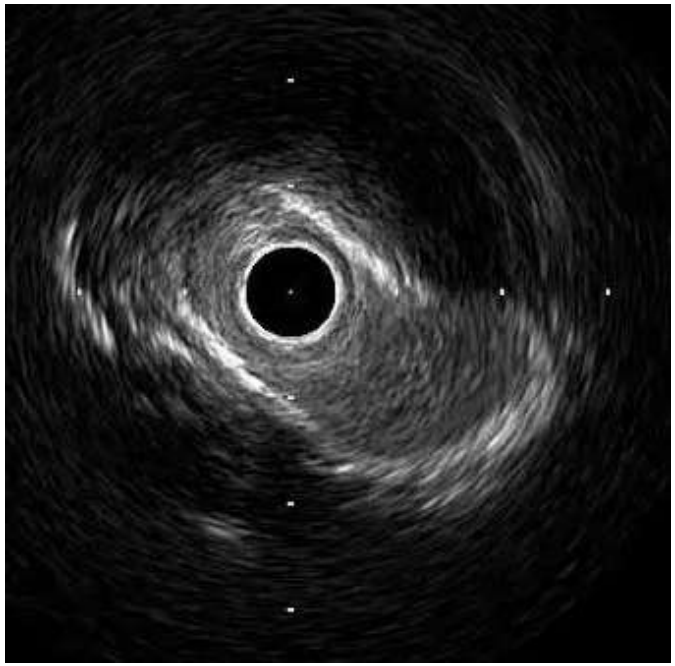

Before Rota 1.75-mm burr.

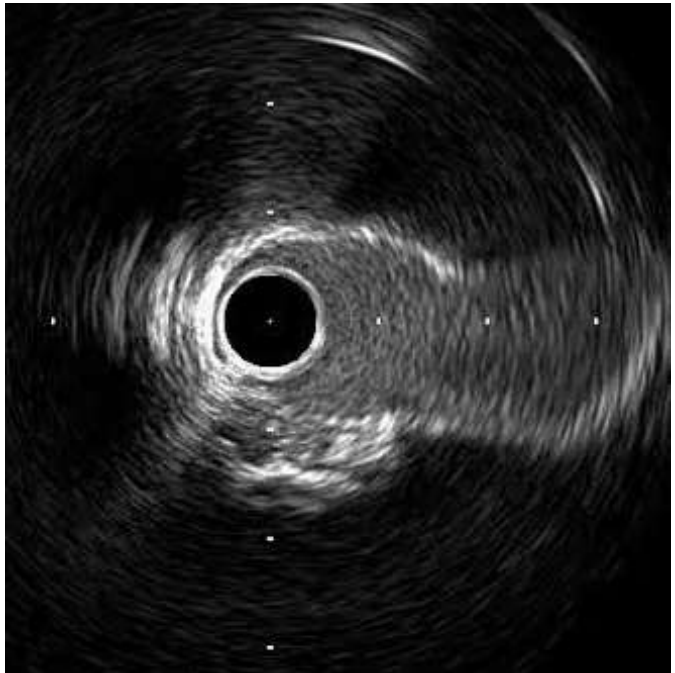

We advanced the Rota-support wire into LAD and ablated the calcified eccentric plaque at Seg6 with a 1.5mm burr.

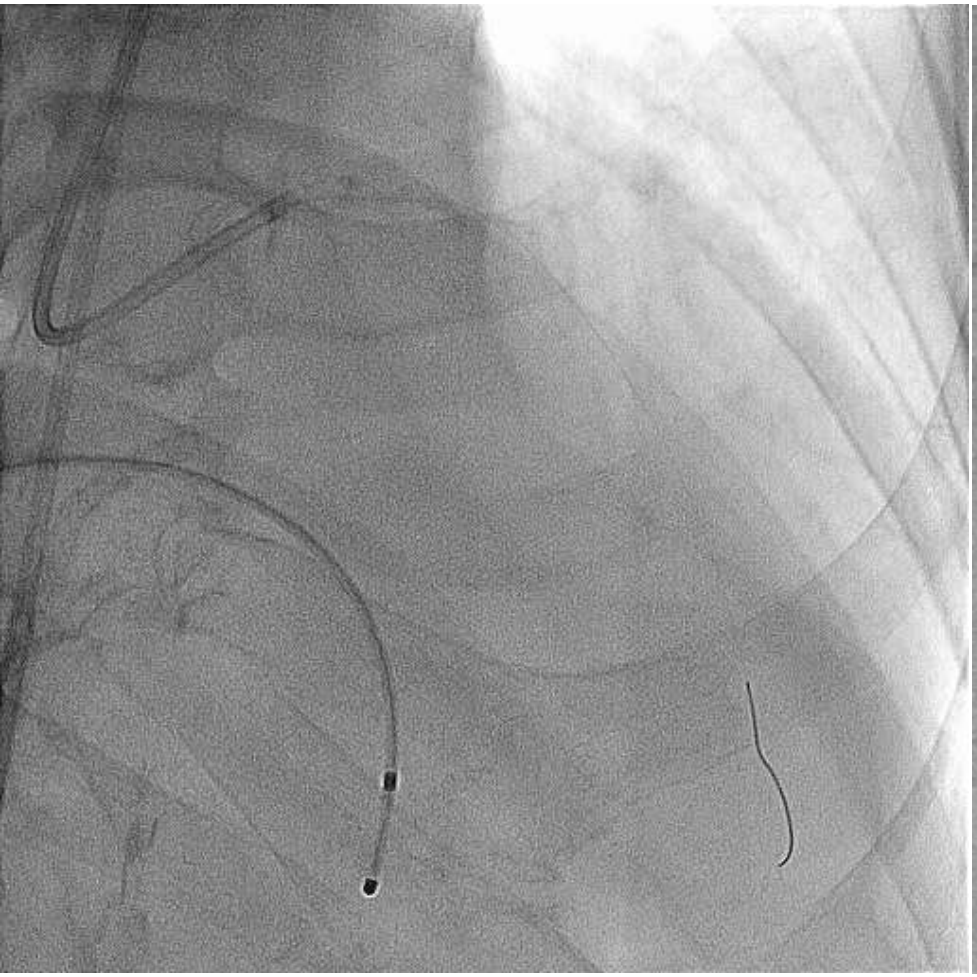

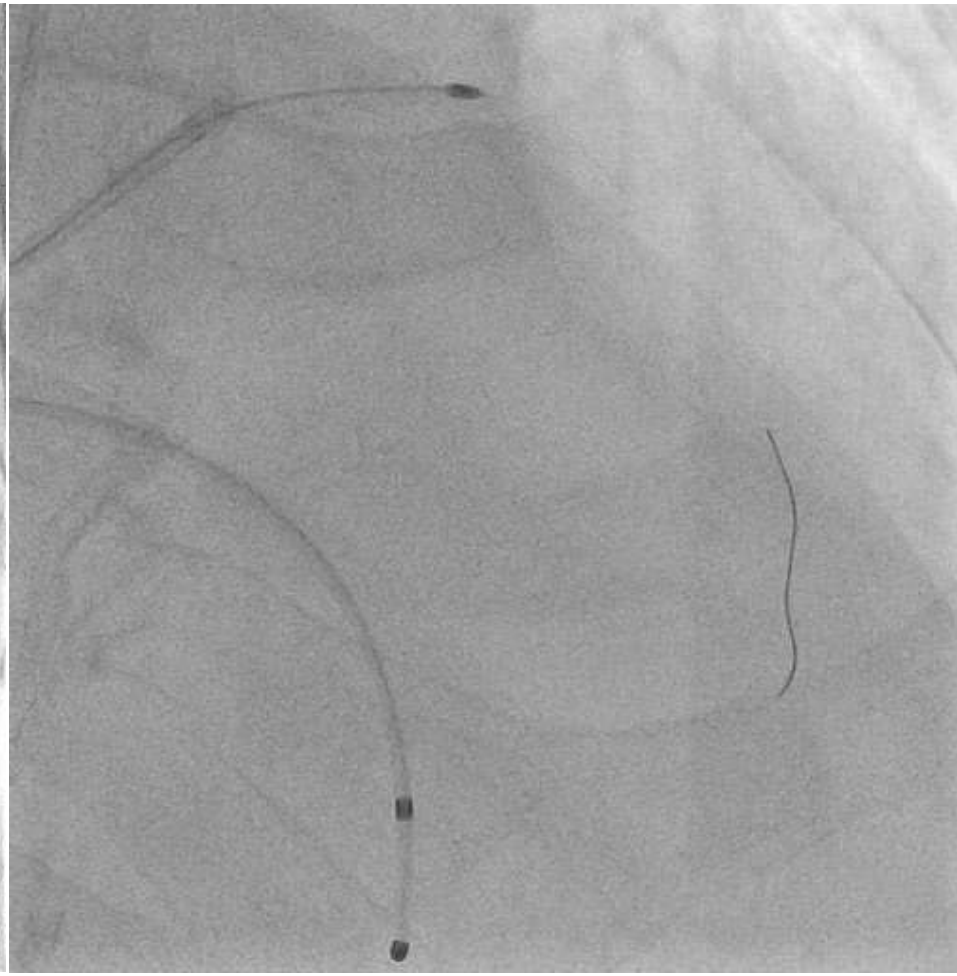

DES was implanted from Seg12 to the mid-part of Seg11.
DES was implanted from Seg6-5, and KBT was performed Seg5-6, Seg5-11 followed by DCB at Seg11.

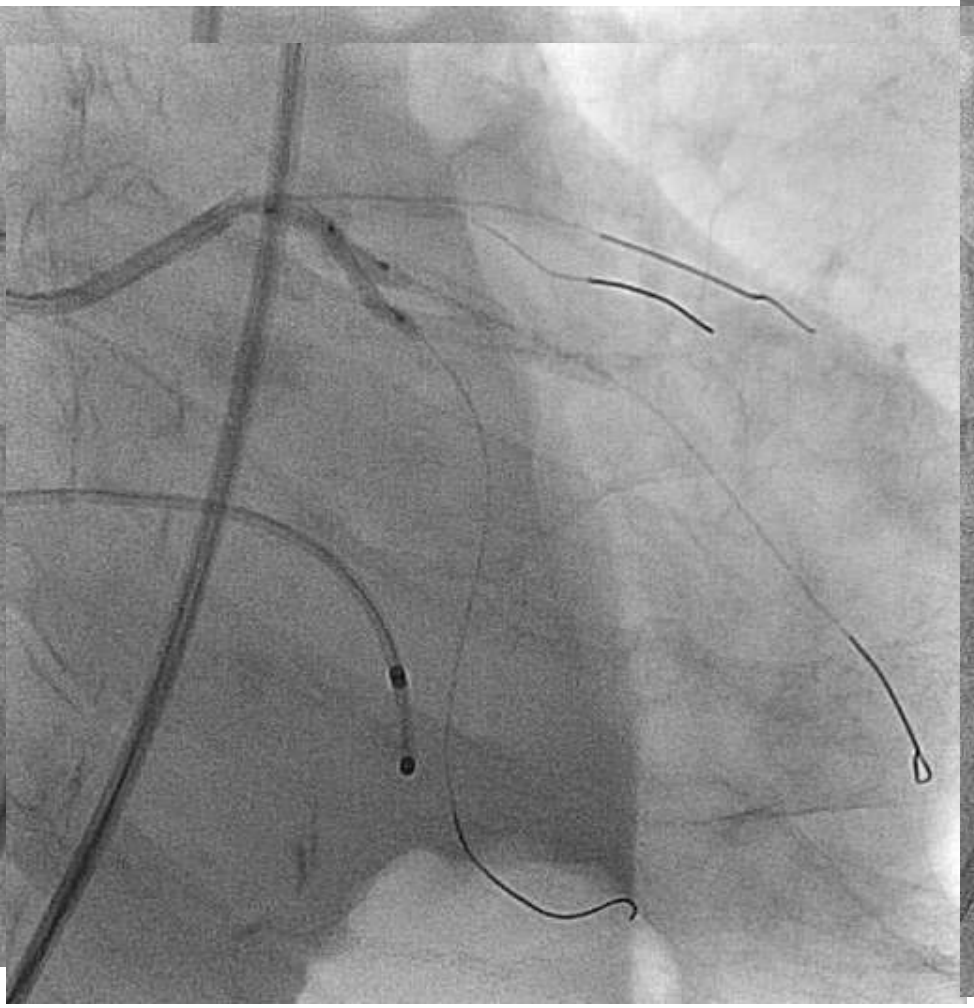

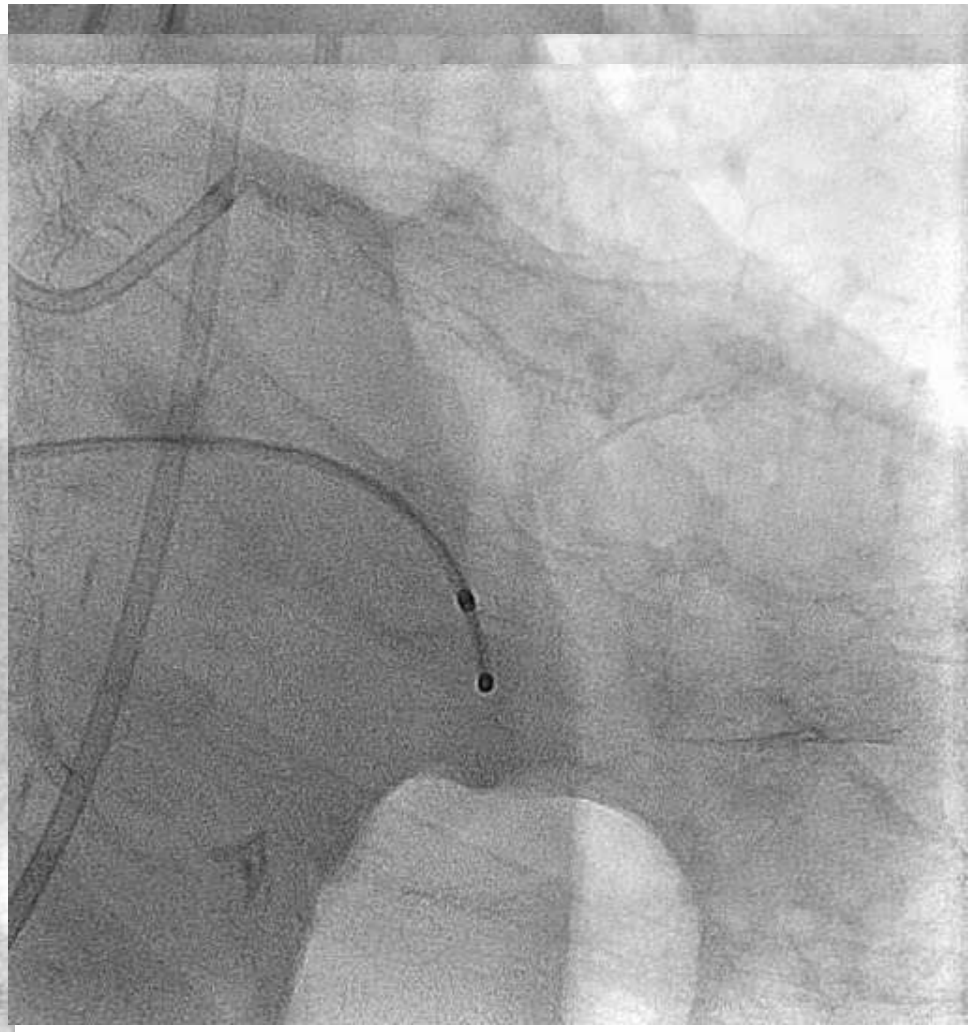

Take home massage

Rotablation with some techniques (Scorering balloons and crushing with PCI stiff wires) is useful to unload calcified lesions, such as, sever calcified lesions which can not be open by POBA and the calcified bifurcations that should be avoided the double stenting.